

# Differences in graft orientation using the transtibial and anteromedial portal technique in anterior cruciate ligament reconstruction: a magnetic resonance imaging study

Michael Elias Hantes · Vasilios C. Zachos ·  
Athanasios Liantsis · Aaron Venouziou ·  
Apostolos H. Karantanas · Konstantinos N. Malizos

Received: 19 October 2008 / Accepted: 23 January 2009 / Published online: 24 February 2009  
© Springer-Verlag 2009

**Abstract** The purpose of this study was to evaluate differences in graft orientation between transtibial (TT) and anteromedial (AM) portal technique using magnetic resonance imaging (MRI) in anterior cruciate ligament (ACL) reconstruction. Fifty-six patients who were undergoing ACL reconstruction underwent MRI of their healthy and reconstructed knee. Thirty patients had ACL reconstruction using the TT (group A), while in the remaining 26 the AM (group B) was used. In the femoral part graft orientation was evaluated in the coronal plane using the femoral graft angle (FGA). The FGA was defined as the angle between the axis of the femoral tunnel and the joint line. In the tibial part graft orientation was evaluated in the sagittal plane using the tibial graft angle (TGA). The TGA was defined as the angle between the axis of the tibial tunnel and a line perpendicular to the long axis of the tibia. The ACL angle of the normal knee in the sagittal view was also calculated. The mean FGA for group A was 72°, while for the group B was 53° and this was statistically significant ( $P < 0.001$ ). The mean TGA for group A was 64°, while for the group B was 63° ( $P = 0.256$ ). The mean intact ACL angle for

group A was 52°, while for the group B was 51°. The difference between TGA and intact ACL angle was statistically significant ( $P < 0.001$ ) for both groups. Using the AM portal technique, the ACL graft is placed in a more oblique direction in comparison with the TT technique in the femoral part. However, there are no differences between the two techniques in graft orientation in the tibial part. Normal sagittal obliquity is not restored with both techniques.

**Keywords** Anterior cruciate ligament reconstruction · Transtibial technique · Anteromedial portal technique · Magnetic resonance imaging

## Introduction

According to many anatomical studies, femoral attachment of the anterior cruciate ligament (ACL) lies deep and low on the medial wall of the lateral femoral condyle [2, 6, 23]. Correct position of the femoral tunnel is a critical point for a successful single bundle ACL reconstruction. In the sagittal plane the femoral tunnel must be in the posterior quadrant of the Blumensaat line [5, 19]. The importance of correct position in the sagittal plane in ACL reconstruction recognized many years ago and incorrect position of the femoral tunnel yields poor clinical results [8, 14, 15]. However, the importance of correct position of an ACL graft in the coronal plane has been underestimated. In the last years, many authors demonstrated the biomechanical advantages of recreation of the obliquity of the ACL graft (like the native ACL) in the coronal plane [13, 18, 21, 22]. In addition, it has been shown that a vertically oriented graft in the coronal plane is associated with poor clinical results resulting in a persistent pivot shift [16].

---

Paper presented at the 6th Biennial ISAKOS Congress, Florence, ITALY, 2007 and 12th ESSKA 2000 Congress, Innsbruck, Austria 2006.

---

M. E. Hantes (✉) · V. C. Zachos · A. Liantsis ·  
A. Venouziou · K. N. Malizos  
Department of Orthopaedic Surgery, Medical School,  
University Hospital of Larissa, University of Thessalia,  
Mezourlo, 41110 Larissa, Greece  
e-mail: hantesmi@otenet.gr

A. H. Karantanas  
Department of Radiology, University Hospital,  
University of Crete, Heraklion, Greece

The most popular technique for femoral tunnel creation in ACL reconstruction is the transtibial (TT) technique [10]. Using this technique the femoral tunnel is drilled through the tibial tunnel and therefore, position of the femoral tunnel is dictated by the tibial tunnel. According to many surgeons correct placement of the femoral tunnel can be achieved using the transtibial technique [13, 22]. However, as it has been demonstrated by Arnold et al. [3] transtibial femoral tunnel drilling does not reach the anatomical site of the ACL insertion at 10 o'clock. Usually with this technique, a position corresponding between 11 and 12 o'clock position could be reached and the graft is placed in a relatively vertical position. In order to overcome these problems many authors recommend the anteromedial (AM) portal technique [9, 11]. Using this technique, the femoral tunnel is drilled through the AM portal while the knee is placed in maximum flexion between 125° and 130°. In this way, the surgeon has more freedom to place the graft in the anatomical position (deep and low in the notch) at 10 or even 9.30 o'clock. Therefore, an oblique (or more horizontal) placement of the graft is achieved close to the course of the native ACL.

The primary goal of this retrospective comparative study was to evaluate graft orientation after ACL reconstruction, using the TT and AM technique for femoral tunnel creation by the same surgeon. The magnetic resonance image (MRI) was chosen as the most accurate imaging modality to evaluate graft position and orientation in both the sagittal and coronal plane. Our hypothesis was that the AM technique would provide a more oblique placement of the graft which is more close to the anatomy of the ACL in comparison to the TT technique, in this single surgeon's series. A secondary aim was to investigate graft orientation in the sagittal plane and to compare the reconstructed with the normal knee.

## Materials and methods

Fifty-six patients who underwent arthroscopic ACL reconstruction by a single surgeon with a four-strand band hamstring (HS) tendon autograft and identical type of fixation (for both the femoral and tibial part) were retrospectively enrolled in this study. All patients were operated in our institution from January 2002 to May 2004. Patients who underwent other major operations in the affected knee were excluded from the study. Finally, patient's agreement to have a postoperative MRI of their operated knee and an intact ACL of their contralateral knee were necessary for inclusion in the study.

Two distinct patient groups were defined. Patients operated between January 2002 and March 2003 underwent ACL reconstruction using the TT technique. This group

consisted of 30 patients. In the second group which consisted of 26 patients, ACL reconstruction was performed through the AM portal. This group of patients operated between March 2003 and May 2004. From March 2003, the senior surgeon changed his technique from TT to AM.

## Surgical technique

Both the semitendinosus and gracilis tendons were used for ACL reconstruction. Graft harvesting was performed through a 2.5-cm longitudinal incision using a tendon stripper. A standard anterolateral portal is used for diagnostic arthroscopy and an anteromedial portal as a working portal. The ACL stump is debrided using arthroscopic scissors and a full radius shaver. A curette is used to perform a notchplasty and to debride the notch.

The tibial tunnel is then created. With the knee at 90° of flexion, the endoscopic aimer is inserted to the knee through the anteromedial portal and is adjusted to 50°. The entry point of the tibial tunnel was placed between the anterior part of the medial collateral ligament and the tibial tubercle. The ACL stump, the PCL and the inner rim of the anterior horn of the lateral meniscus are used as landmarks to identify the optimal position. A guide pin is then drilled into the joint and a cannulated reamer equal to the graft diameter is used to create the tibial tunnel. The technique was identical for both (TT and AM) groups.

In the TT group, the femoral tunnel was drilled through the tibial tunnel. To do this a femoral guide with an appropriate offset (e.g., with an 8-mm graft a femoral guide with a 5-mm offset is used) is introduced into the joint through the tibial tunnel and it was placed in the posterior aspect of the notch. Flexion of the knee was approximately 70–90°. Then a K-wire was placed in a position which has been determined by the femoral guide (usually at approximately the 11 o'clock position for the right knee or at approximately the 1 o'clock position for the left knee). The K-wire was then over-drilled with a reamer corresponding to the size of the graft diameter and to a depth of 30 mm. Graft fixation was performed with 2 RigidFix pins (DePuy Mitek, Raynham, MA) in the femoral tunnel. The Rigidfix guide frame was inserted into the femoral tunnel through the tibial tunnel. Tibial fixation was performed with the Intrafix system (DePuy Mitek, Raynham, MA).

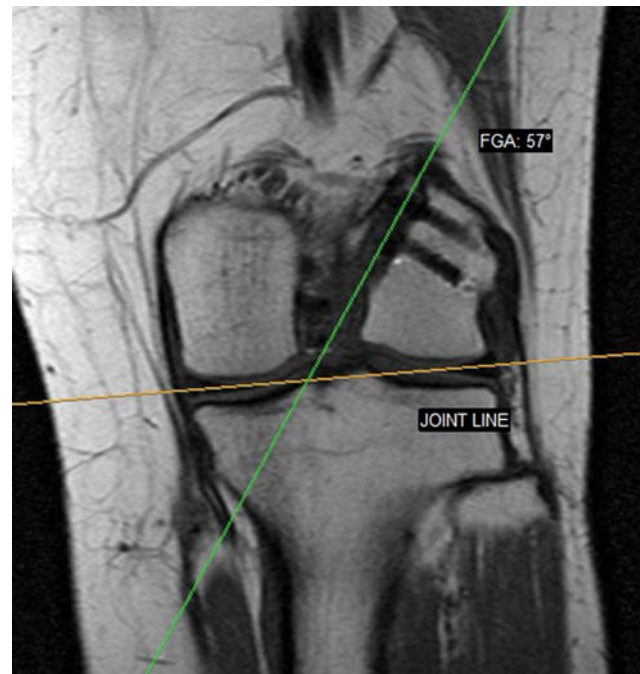In the AM group the femoral tunnel was drilled through the anteromedial portal. The knee was placed in maximum flexion between 125° and 130°. Again, a femoral guide with an appropriate offset is introduced into the joint through the anteromedial portal. With the aim of the femoral guide a K-wire is then placed into the center of the anatomic insertion of the ACL (usually at approximately the 10 o'clock position for the right knee or at approximately the 2 o'clock position for the left knee). With the

knee in full flexion the K-wire is over-drilled with a reamer corresponding to the size of the graft diameter and to a depth of 30 mm. Graft fixation was performed with 2 RigidFix pins (DePuy Mitek, Raynham, MA) in the femoral tunnel. However, the Rigidfix guide frame was inserted into the femoral tunnel through the anteromedial portal in this group of patients. Similarly, tibial fixation was performed with the Intrafix system (DePuy Mitek, Raynham, MA).

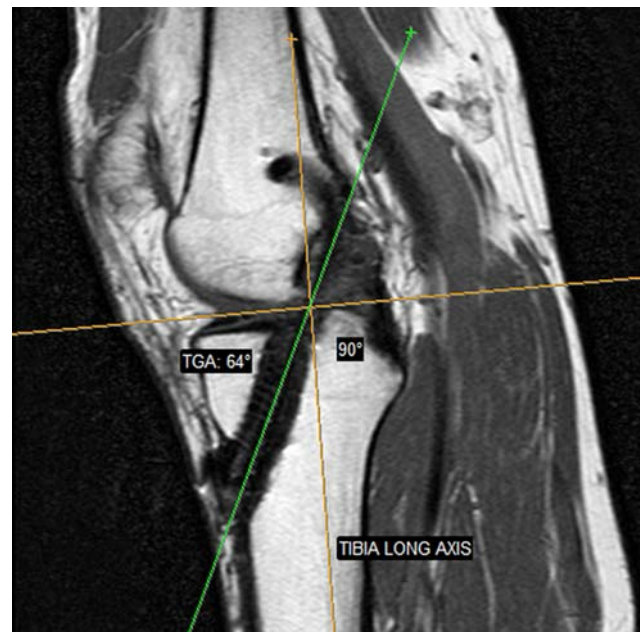
#### MRI protocol and measurements

All patients included in this study, underwent an MRI examination on both the operated and the non-operated knee at least 1 year after ACL reconstruction. Both legs were positioned in the gantry. The examined knee was placed in the coil in full extension and 10–15° of external rotation with a supporting device to assure comfort and immobilization. MRI was performed with a 1.0-T MR imager (Philips Intera; Philips Medical Systems, Best, The Netherlands) by using a quadrature coil. The MRI protocol included one pulse sequence (T1-w Spin Echo) in sagittal, coronal, and transverse planes and the parameters were as follows: 550/15 (TR ms/TE ms), matrix of 304 × 512, field of view 16 × 14 cm, four signal excitations, 4-mm slice thickness for the coronal and sagittal acquisitions and 500/20 (TR msec/TE msec), matrix of 304 × 512, field of view 16 cm × 14 cm, three signal excitations, 3-mm slice thickness for the transverse acquisition. No fat suppression was applied to avoid susceptibility artifacts from the previous operation (ACL reconstruction). The main imaging protocol included the sagittal and coronal planes. For the operated leg, an image in the coronal plane that showed the femoral tunnel in almost its entire length was used. Also, in the sagittal plane an image that showed the tibial tunnel in almost its entire length was used. For the non-operated leg an image in the sagittal plane that showed the intact ACL was used.

Orientation of the ACL graft was calculated in the coronal plane using the femoral graft angle (FGA); the FGA was defined as the angle between the axis of the femoral tunnel and the joint line (Fig. 1). In the sagittal plane, graft orientation was calculated using the tibial graft angle (TGA); the TGA was defined as the angle between the axis of the tibial tunnel and a line perpendicular to the long axis of the tibia (Fig. 2). In the non-operated leg, the angle of the intact ACL was calculated by two lines: a line perpendicular to the long axis of the tibia and a line along the intact ACL. One senior musculoskeletal radiologist and one orthopedic surgeon blinded to the procedure performed all the measurements.



**Fig. 1** The femoral graft angle (FGA) is shown on this coronal MRI image. A line parallel to the axis of the femoral tunnel and the joint line were used to calculate the FGA. In this case the FGA is 57° (ACL reconstruction with AM portal technique)



**Fig. 2** The tibial graft angle (TGA) is shown on this sagittal MRI image. A line parallel to the axis of the tibial tunnel and a line perpendicular to the long axis of the tibia were used to calculate the TGA. In this case the TGA is 64° (ACL reconstruction with TT technique)

## Statistics

The independent samples *t* test was used for comparison between the groups. The data were analyzed with the SPSS statistical package (SPSS ver.12, Chicago, Illinois). To determine interobserver variability, interclass correlation coefficient was calculated. Significance was set at  $P < 0.05$ .

## Results

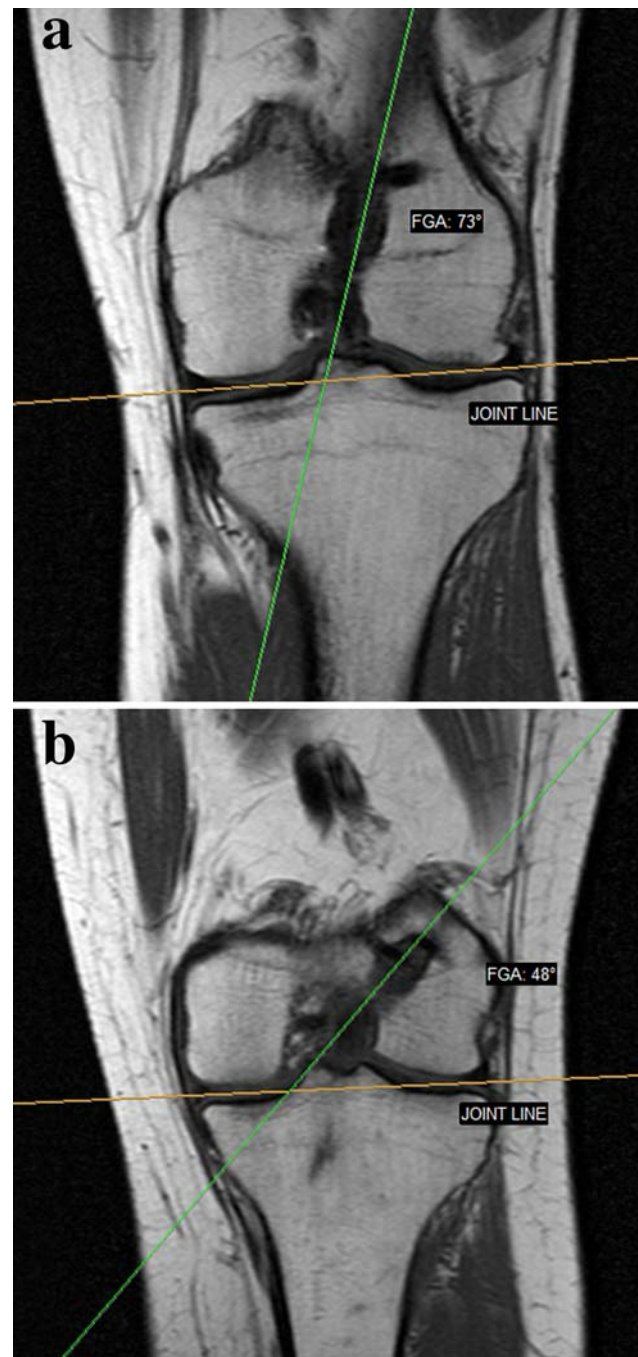
There were 28 males and 2 females with a mean age of 25.6 years in the TT group and 26 males and 4 females with a mean age of 27.2 years in the AM group. The mean time for the MRI study was 18.4 months (range 15–26) for the TT group and 22.6 months (range 17–28) for the AM group.

The mean FGA for the TT group was  $71^\circ$  ( $76^\circ$ – $66^\circ$ ) while for the AM group it was  $52^\circ$  ( $46^\circ$ – $59^\circ$ ). This difference was statistically significant ( $P < 0.001$ ) (Fig. 3). The mean TGA for group was  $64^\circ$  ( $57^\circ$ – $67^\circ$ ), while for the AM group it was  $63^\circ$  ( $57^\circ$ – $66^\circ$ ) but this was not statistically significant (Fig. 4). The mean angle of the intact ACL angle for the TT group A was  $52^\circ$  ( $45^\circ$ – $54^\circ$ ), while for the AM group was  $51^\circ$  ( $46^\circ$ – $56^\circ$ ) (Fig. 5). The difference between TGA and intact ACL angle was statistically significant ( $P < 0.001$ ) for both groups.

The interobserver variability regarding MRI measurements were excellent with intraclass correlation coefficients of 0.91, 0.95 and 0.94 for the FGA, TGA and intact ACL angle, respectively.

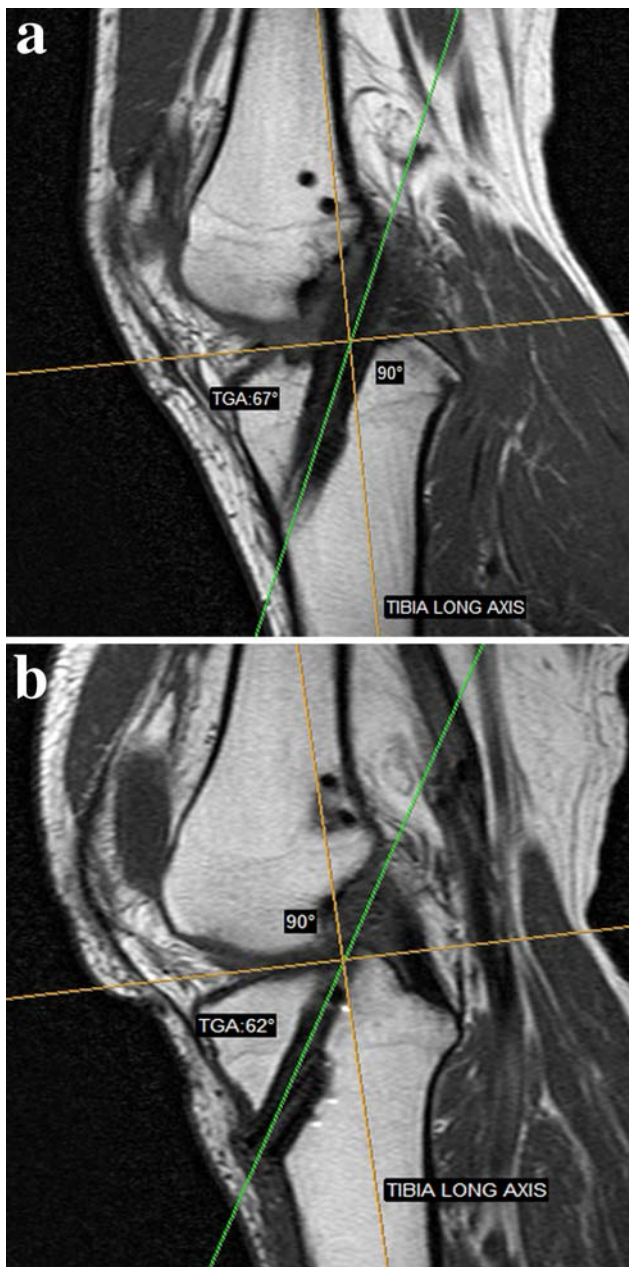
## Discussion

In this study, two different techniques for femoral tunnel creation in ACL reconstruction were evaluated. Our study demonstrated that the AM technique results in a significantly more oblique femoral tunnel in the coronal plane in comparison to the TT technique. The femoral tunnel was approximately  $20^\circ$  more vertical in the TT group in comparison to the AM group and this was statistically significant. According to biomechanical studies an oblique femoral tunnel placement in the coronal plane improves rotatory knee stability in comparison to a more vertical position [18, 21]. Probably the biomechanical and clinical advantages of the obliquity of the graft in the coronal plane are due to its anatomic placement, low in the notch in the anatomical footprint of the native ACL. This position usually corresponds to the so-called 10 o'clock position. Placement of the graft high in the notch results in a more vertical graft. This position usually corresponds to the



**Fig. 3** Comparison of graft obliquity in the coronal plane between (a) a reconstructed knee with the TT technique (FGA is  $73^\circ$ ) and (b) a reconstructed knee with the AM portal technique (FGA is  $48^\circ$ )

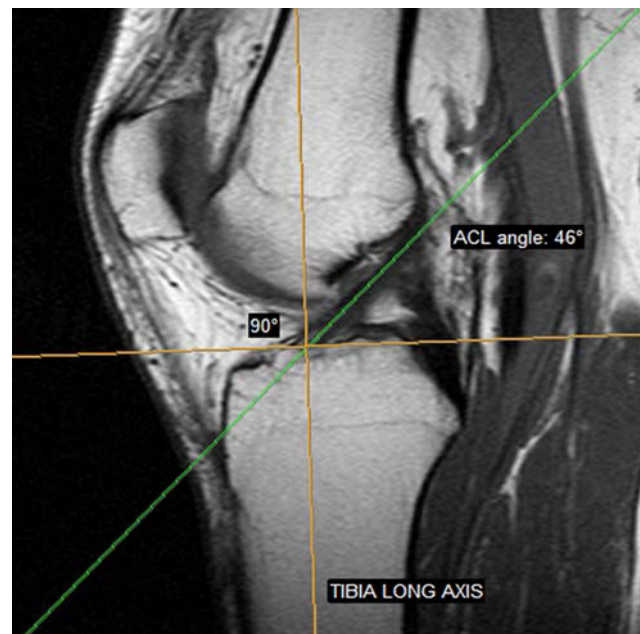
so-called 11 or even 11.30 o'clock position. In our study, graft obliquity was not determined by the o'clock description because this system lacks precision and is dependent on subjective interpretation to some extent. Measurement of graft obliquity was performed in our study by using the MRI images and consistent landmarks (axis of the tunnel and a vertical line to the joint line). This method



**Fig. 4** Comparison of graft obliquity in the sagittal plane between (a) a reconstructed knee with the TT technique (TGA is 67°) and (b) a reconstructed knee with the AM portal technique (FGA is 62°)

is objective and accurate, since interobserver variability was excellent according to our results.

Loh et al. [18] as well as Scopp et al. [21] demonstrated in cadaver biomechanical models that reconstructing the femoral tunnel at the oblique anatomic origin of the ACL, rotational stability of the knee is more effectively restored. Clinically, a vertically oriented graft is related to residual pivot shift although anterior tibial translation can be restored. Lee et al. [17] reported that in a subset of patients with a vertical graft orientation, clinical results (pivot shift,



**Fig. 5** The intact ACL angle (from a normal knee) is shown on this sagittal MRI image. In this case the ACL angle is 46°

KT-1000 measurements) and Lysholm score was significantly worse in comparison to patients with a more oblique graft placement. Similarly, Jepsen et al. [14] found that a change in the femoral tunnel placement from 1 o'clock position to 2 o'clock position (more oblique graft) results in a significant difference in the scores on the IKDC evaluation form. Therefore, a better clinical result could be expected in patients with an oblique orientated graft. Unfortunately, we cannot correlate our MRI findings with the clinical results at that time since the two groups of our patients are under clinical evaluation and the clinical results will be reported in the near future.

According to our results, the TT technique is less ideal in comparison to AM technique to create an oblique femoral tunnel in the coronal plane. Arnold et al. [3] in a cadaver study found that using the TT technique (through a correctly placed tibial tunnel) the graft is placed in a non-anatomical position higher in the notch in most of the cases. Similarly, in other cadaver studies it was found that using the AM portal technique the center of the femoral tunnel is significantly closer to the center of the femoral ACL footprint in comparison to the TT technique [7, 16]. However, other surgeons report that an oblique femoral tunnel can be obtained with the TT technique [19]. Simmons et al. [13] reported that it is possible for the surgeon to place the femoral tunnel at 60° in the coronal plane with the transtibial technique if he/she controls the angle of the tibial tunnel. To achieve this one has to create the entry point of the tibial tunnel at the junction of the superior border of the pes anserine tendons and anterior border of

the medial collateral ligament. In this way a more oblique tibial tunnel is created and it is easier to reach the anatomic origin of the ACL [20]. In our study, the entry point of the tibial tunnel was placed between the anterior part of the medial collateral ligament and the tibial tubercle and probably this fact affected our results. However, limitations still exist with the TT even by modifying the entry point of the tibial tunnel. As it has been shown by Heming et al. [12] it is possible to achieve a proper position of the ACL graft using the TT technique, but the tibial tunnel must start close to the joint line (only 14 mm inferior to the joint line).

Ahn et al. [1] using the TT technique and hamstring autograft for their ACL reconstruction found a mean coronal graft angle of 17° in their MRI study which is similar to our results with the TT group. However, comparison to our AM group is not possible because they did not use the AM technique in their study. In another MRI study, Lee et al. [18] reported similar results with a mean coronal graft of 16.5° and good clinical results. Interestingly, in the same study, patients with a more vertical graft (mean coronal angle of 10.5°) had worse results.

In the sagittal plane, neither technique was effective to restore normal ACL obliquity. According to our results, graft obliquity in reconstructed patients with the TT and AM was similar and significantly more vertical in comparison to the native ACL. Our results, are in accordance with other studies (using similar MRI protocols) which reported graft obliquity in reconstructed patients between 63° and 70° [1, 4, 17]. In our opinion, this problem is created because the surgeon chooses to place the tibial tunnel slightly posterior to the anatomic ACL insertion in order to avoid roof impingement. Another explanation might be that many surgeons prefer to drill their tibial tunnel in a more vertical way because they think that a tunnel of sufficient length is achieved in this way. However, a more oblique tunnel in the sagittal plane can produce also a sufficient length of the tibial tunnel as it has been shown by many authors [13, 22]. This means that the surgeon is not able to reproduce the orientation of the native ACL in the sagittal plane using the techniques which are available today. Although it has been reported that anterior–posterior knee displacement is restored, we believe that a vertical graft in the sagittal plane may influence graft function and there is room for improvement regarding our surgical technique.

There are some limitations of this study. First of all its retrospective nature had less scientific significance. There was no randomization and no clinical correlation. However, our study has the advantages of a consecutive series of patients, operated by the same surgeon using the same graft and fixation technique. In addition, MRI was chosen as the

most accurate imaging modality to evaluate graft position and orientation in both the sagittal and coronal plane.

## Conclusion

Our results showed that in our hands, the AM portal technique in ACL reconstruction results in a significantly more oblique femoral tunnel in the coronal plane in comparison to the TT technique. This is because drilling the femoral tunnel independent of the tibial tunnel the surgeon has more freedom to place the graft in an anatomical (more oblique) position close to the native ACL. However, graft obliquity in the sagittal plane could not be restored with either technique and the graft was significantly more vertical than the normal ACL. The clinical results will be reported in the future in a long-term follow-up study to determine if there is any clinical implication of these findings.

## References

1. Ahn JH, Lee SK, Yoo JC, Ha HC (2007) Measurement of the graft angles for the anterior cruciate ligament reconstruction with transtibial technique using postoperative magnetic resonance imaging in comparative study. *Knee Surg Sports Traumatol Arthrosc* 15:1293–1300
2. Arnoczky SP (1983) Anatomy of the anterior cruciate ligament. *Clin Orthop Relat Res* 172:19–25
3. Arnold MP, Kooloos J, van Kampen A (2001) Single incision technique misses the anatomical femoral anterior cruciate ligament insertion: a cadaver study. *Knee Surg Sports Traumatol Arthrosc* 9:194–199
4. Ayerza MA, Muscolo DL, Costa-Paz M, Makino A, Rondon L (2003) Comparison of sagittal obliquity of the reconstructed anterior cruciate ligament using magnetic resonance imaging. *Arthroscopy* 19:257–261
5. Bernard M, Hertel P, Hornung H, Cierpinski T (1997) Femoral insertion of the anterior cruciate ligament. Radiological quadrant method. *Am J Knee Surg* 10:14–21
6. Colombet P, Robinson J, Christel P et al (2006) Morphology of anterior cruciate ligament attachments for anatomic reconstruction: a cadaveric dissection and radiographic study. *Arthroscopy* 22:984–992
7. Gavriilidis I, Mosis EK, Pakos EE, Georgoulis AD, Mitsionis G, Xenakis TA (2008) Transtibial versus anteromedial portal of the femoral tunnel in anterior cruciate ligament reconstruction: a cadaveric study. *Knee* 15:364–367
8. Getelman MH, Friedman MJ (1999) Revision anterior cruciate ligament reconstruction surgery. *J Am Acad Orthop Surg* 7:189–198
9. Hantes ME, Dailiana Z, Zachos VC, Varitimidis SE (2006) Anterior cruciate ligament reconstruction using the Bio-TransFix femoral device and anteromedial portal technique. *Knee Surg Sports Traumatol Arthrosc* 14:497–501
10. Harner CD, Fu F, Irrgang JJ, Vogrin TM (2001) Anterior and posterior cruciate ligament reconstruction in the new millennium: a global perspective. *Knee Surg Sports Traumatol Arthrosc* 9:330–336

11. Harner CD, Honkamp NJ, Ranawat AS (2008) Anteromedial portal technique for creating the anterior cruciate ligament femoral tunnel. *Arthroscopy* 24:113–115
12. Heming J, Rand J, Steiner M (2007) Anatomical limitations of transtibial drilling in anterior cruciate ligament reconstruction. *Am J Sports Med* 35:1708–1715
13. Howell SM, Gittins ME, Gottlieb JE, Traina SM, Zoellner TM (2001) The relationship between the angle of the tibial tunnel in the coronal plane and loss of flexion and anterior laxity after anterior cruciate ligament reconstruction. *Am J Sports Med* 29:567–574
14. Jespen CF, Lundberg-Jensen AK, Faunoe P (2007) Does the position of the femoral tunnel affect the laxity or clinical outcome of the anterior cruciate ligament reconstructed knee? A clinical prospective randomized, double-blind study. *Arthroscopy* 23:1326–1333
15. Johnson DL, Swenson TM, Irrgang JJ, Fu FH, Harner CD (1996) Revision anterior cruciate ligament surgery: experience from Pittsburgh. *Clin Orthop Relat Res* 325:100–109
16. Kaseta MK, DeFrate LE, Charnock BL, Sullivan RT, Garrett WE Jr (2008) Reconstruction technique affects femoral tunnel placement in anterior cruciate ligament reconstruction. *Clin Orthop Rel Res* 466:1467–1474
17. Lee MC, Seong SC, Lee S, Chang CB, Park YK, Jo H, Kim CH (2007) Vertical femoral tunnel placement results in rotational knee laxity after anterior cruciate ligament reconstruction. *Arthroscopy* 23:771–778
18. Loh JC, Fukuda Y, Tsuda E, Steadman RJ, Fu FH, Woo SL (2003) Knee stability and graft function following anterior cruciate ligament reconstruction: comparison between 11 o'clock and 10 o'clock femoral tunnel placement. *Arthroscopy* 19:297–304
19. Pinczewski LA, Salmon LJ, Jackson WF, von Bormann RB, Haslam PG, Tashiro S (2008) Radiological landmarks for placement of the tunnels in single-bundle reconstruction of the anterior cruciate ligament. *J Bone Joint Surg Br* 90:172–179
20. Raffo SC, Pizzarello P, Richmond JC, Pathare N (2008) A reproducible landmark for the tibial tunnel origin in anterior cruciate ligament reconstruction: avoiding a vertical graft in the coronal plane. *Arthroscopy* 24:843–845
21. Scopp JM, Jasper LE, Belkoff SM, Moorman CTIII (2004) The effect of oblique femoral tunnel placement on rotational constraint of the knee reconstructed using patellar tendon autografts. *Arthroscopy* 20:294–299
22. Simmons R, Howell SM, Hull ML (2003) Effect of the angle of the femoral and tibial tunnels in the coronal plane and incremental excision of the posterior cruciate ligament on tension of an anterior cruciate ligament graft: an in vitro study. *J Bone Joint Surg Am* 85:1018–1029
23. Takahashi M, Doi M, Abe M, Suzuki D, Nagano A (2006) Anatomical study of the femoral and tibial insertions of the anteromedial and posterolateral bundles of human anterior cruciate ligament. *Am J Sports Med* 34:787–792